



<https://africanjournalofbiomedicalresearch.com/index.php/AJBR>

Afr. J. Biomed. Res. Vol. 28(2s) (February 2025); 1328-1332

Research Article

“A Clinical Case Study Of Sariva Kshara Sutra With Partial Fistulectomy In The Management Of Bhagandara (Fistula-In-Ano)”

Dr. Shah Niket Devendra¹, Dr. Om Prakash Dave², Dr. Shailesh Jaiswal³

¹ PhD. Scholar, Department of PhD. Studies in Shalya Tantra, Parul Institute of Ayurveda, Parul University, Limda, Waghodia, Vadodara, Gujarat. -391760

^{2*} Professor of Department of Shalya Tantra, Parul Institute of Ayurveda, Parul University, Limda, Waghodia, Vadodara, Gujarat. -391760

³ Associate Professor of Department of Shalya Tantra, Parul Institute of Ayurveda & Research, Parul University, Limda, Waghodia, Vadodara, Gujarat. -391760

***Corresponding Author :** Dr. Shah Niket Devendra

*E-mail: nds9989@yahoo.com

Abstract: -

Ayurveda, *Bhagandara* is considered as one of the *Ashta Mahagaroga* (8 major disease) by *Sushruta* due to more recurrence rate. In present era anorectal disorders are increasing, due to sedentary lifestyle and other factors. The word *Bhagandara* is composed of 2 words *Bhaga* and *Darana*, it is a common disease occurring in Anorectal region around the anus which extends up to Genitalia. The formation of *Pidika* leads to development of *Bhagandara* it is characterized by opening around the *Guda Pradesha* with painful Discharge. *Bhagandara* is treated by different modalities modern science but till day no single modalities have proven to be complete one for *Fistula*, *Kshara Sutra* therapy is the unique specialized Para surgical procedure which is used in *Fistula in Ano*. The present study was undertaken to assess the modified way to treat *fistula-in-ano* with *Sariva Kshara Sutra with partial fistulectomy*. Case was taken from OPD/IPD of SHAH PILES FISTULA HOSPITAL, AHMEDABAD

CASE 1: - Age 23 yrs. Male Patient presenting with pain, swelling, discharge in scrotal to anterior anal canal (scrotal extension) was examined in Shalya OPD treated with *Sariva Kshara Sutra with partial fistulectomy* considering it an ideal procedure in the treatment of *Bhagandara* as it cuts and cures the unhealthy tissue present inside the fistulous tract preserving the Sphincter.

Keywords: *Fistula in Ano; Bhagandara; sariva kshara sutra with partial fistulectomy; recurrent fistula*

***Author of correspondence: Email:** nds9989@yahoo.com

Received: 25/02/2025

Accepted: 04/03/2025

DOI: <https://doi.org/10.53555/AJBR.v28i2S.7058>

© 2025 The Author(s).

This article has been published under the terms of Creative Commons Attribution-Noncommercial 4.0 International License (CC BY-NC 4.0), which permits noncommercial unrestricted use, distribution, and reproduction in any medium, provided that the following statement is provided. “This article has been published in the African Journal of Biomedical Research”

Introduction: -

Bhagandara can be correlated with *fistula in ano*, *Bhagandara* means which cause splitting or discontinuity in the region of *Bhaga*, *Guda*, *Basti*

region.^[1] It is one among *Ashtamahagada*,^[2] in modern *fistula* word is derived from a Latin word, a reed, pipe, or flute. It is an abnormal communication between anal canal and rectum with exterior (perianal skin) is called

“A Clinical Case Study Of Sariva Kshara Sutra With Partial Fistulectomy In The Management Of Bhagandara (Fistula-In-Ano)”

fistula in ano,^[3] it usually results from an anorectal abscess which burst spontaneously or opened in adequately.

In this study we found the recurrent fistula extended up to base of the scrotum in which pain, swelling, redness, pus discharge from base of the scrotum. Goodsall’s Rule for predicting the tract of fistula is diagnosed with flexible copper probe it opens into the anterior anal canal.

Application of *Kshara Sutra* in anorectal disease has become more popular due to its easy approach and low rate of recurrence.

In this case study, *Fistula in ano* was treated by *Sariva Kshara Sutra with partial fistulectomy* which was cured, and no further complaints and recurrence were found during and follow up period. It is more important among *Shashtra* and *Anushastra Karma*, *Kshara* having the *Chedana*, *Bhedana*, *Lekhana* also *Tridoshaghna* properties

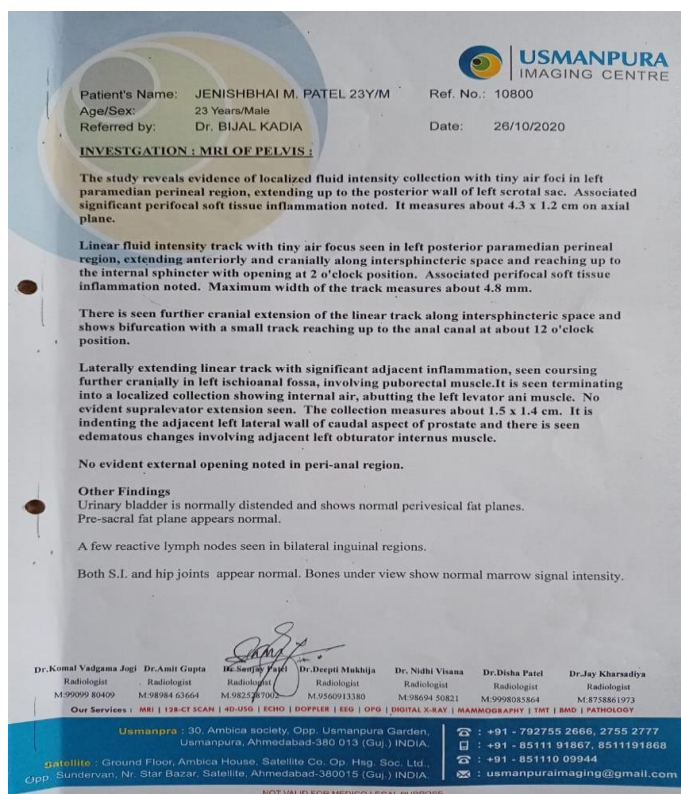
Case report:-

Gender - Male

Age - 23 yrs.

Occupation – Clerk at Kalupur Bank

MRI Report:-



Date of admission - 29/10/2020 Date of recovery - 13/01/2021

Chief complaints and duration - Patient complaints of pain, swelling, since the last 7-8 days.

H/O Present illness

23 yrs. young male patient present with complaints of painful swelling with discharge at anterior aspect of base of scrotum, with induration on 28/10/2020 at our OPD. Presently, on examination patient had discharging wound in the anterior perineum below the scrotum was very painful with tenderness, diagnosis was confirmed by MRI on 26/10/2020. Suggestive of high scrotal anal fistula internal opening at 12 o clock position. Recurrence of fistula in Ano found.

No past medical History

General Examination

- GC – moderate
 - CVS - S1 S2 Heard
 - Pulse - 82/min, BP-120/70mmhg
 - RS - B/L Air entry is clear
 - Digestive system - Appetite –Normal, Bowel- Normal
- On local examination

Preparation of *Kshara Sutra*

Snuhi Ksheera = 11 coatings

Snuhi Ksheera + *Sariva Kshara* = 7 coatings

Snuhi Ksheera + *Haridra Churna* = 3 coatings

This was prepared in the hospital using Barbour’s linen thread No. 20, one coating was applied each day and kept for drying the *Kshara Sutra* cabinet. A total of 21 days was needed to complete the preparation of thread. After these threads were cut in 2 sizes medium length

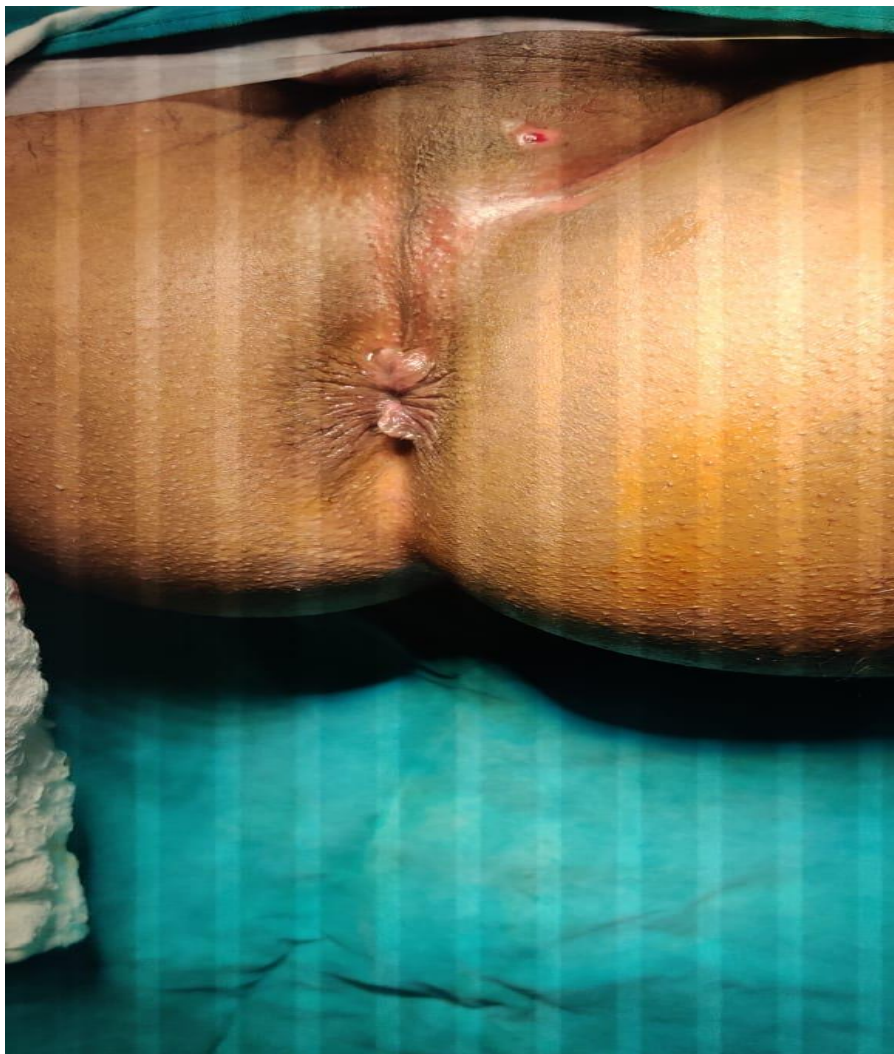
25cm, small 16cm length and packed in a sterile sealed pack after packing in the UV cabinet with a small pack of silica inside to absorb moisture, all of these were packed in airtight container and stored keep it away from contact with any moisture.^[5]

As a Pre-operative measure’s patient is advised to routine investigations like CBC, PLT, CT, BT, RBS, HIV, HbSag, CREATE, SGPT, URINE ROUTINE was

done, all reports found within normal limit. Then patient

consent was taken and posted for operation.

Pre-operative



Under Spinal Anesthesia **first the patient will be kept in lithotomy position and perianal region will be cleaned with**

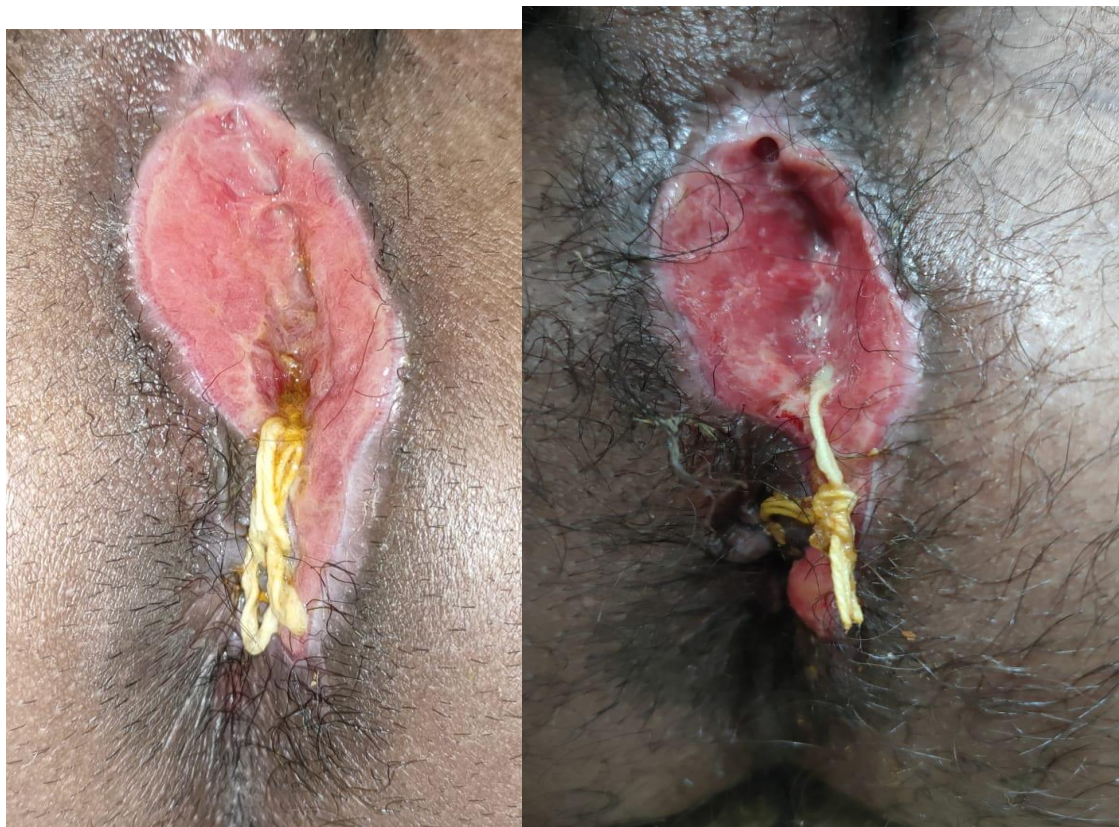antiseptic lotions and draped. Looking at the type of Bhagandara, partial fistulectomy is done leaving the sphincter. Later gloved finger will gently be introduced into the rectum. Then a suitable selected probe will be passed through the external opening of fistula. The tip of the probe will be forwarded along the path of least resistance and will be guided by the finger in rectum to reach into the lumen of anal canal through the internal opening and its tip will be finally directed to come out

of anal orifice. Then a suitable length of surgical linen thread No.20 will be taken and threaded into the eye of probe. Thereafter the probe will be pulled out through the anal orifice, to leave the thread behind in the fistulous track. The two ends of the thread will be then tied together with a moderate tightness outside the anal canal.

Post operative:-

Proper analgesics & anti biotics were prescribed along with sitz bath with proper dressing was given

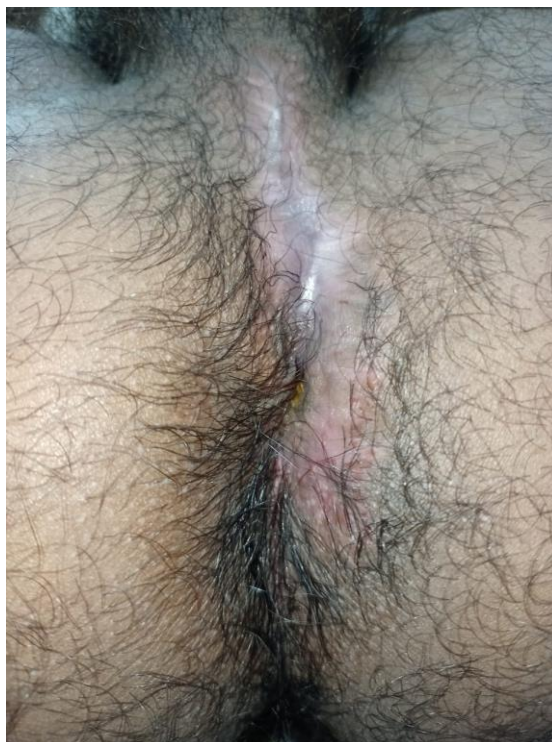
“A Clinical Case Study Of Sariva Kshara Sutra With Partial Fistulectomy In The Management Of Bhagandara (Fistula-In-Ano)”



follow up:-

Patient was asked to visit hospital every week for observation. After 20 days of surgery surgical linen thread No.20 will be replaced by Sariva Kshara sutra and that it will be kept on changing every week till cut through and the wound is healed.

Final result:-



OBSERVATION

Initially the wound was allowed to heal by itself with proper betadine and hydrogen peroxide dressing the

intersphincteric length of track was 2.5 cm. which got cut through. Patient was asked to visit hospital every week till complete healing was achieved. No sign and

symptom of recurrence were observed.

CONCLUSION

Now a days *Kshara Sutra* is the first choice of treating the cases of fistula in ano even in recurrent and complex high anal fistulas. Giving the best results *Kshara Sutra with partial fistulectomy* requires minimal general surgical setup, equipment's, and instruments to achieve the goal of treatment it is necessary to practice *Kshara Sutra* therapy by surgeons. It helps in formation of healthy granulation tissue there by inducing a long healing pattern in depth of tissue, it also removes fibrous tissue and ultimately drains creating a healthy base for healing tract preserving the sphincters.

Conflicts of Interest Statement

"The authors declare no conflicts of interest."

Funding Sources

"This research received no external funding."

Ethical Approval

The study involved human subjects, Ethical approval details: "This study was approved by the [PIA-IECHR], Approval Number [PU/PIA/IECHR/2019/204]."

References

1. Shastri Kaviraj Ambikadatta, Sushrutan Samhita, Ayurveda Tatva Sandeepika, 2016 edition, Varanasi, Chaukhambha Sanskrit Samsthana, Nidana Sthana,4/4, page no,317
2. Shastri Kaviraj Ambikadatta, Sushruta Samhita, Ayurveda Tatva Sandeepika, Hindi commentary, 1997th edition, Reedition 2016, Varanasi, Chaukhamba Sanskrit Samsthana, Sutrasthana,30/4-5, page no,165
3. Shenoy K Rajgopal, Shenoy Anita, Manipal Manual of Surgery, 4th edition 2014, New delhi, CBS Publishers, p799
4. Shastri Kaviraj Ambikadatta, Sushruta Samhita, Ayurveda Tatva Sandeepika, 2016 edition, Varanasi, Chaukhambha Sanskrit Samsthana, Sutrasthana,11/3,p-45
5. Deshapande, P G Pathak SN, The treatment of Fistula in ano with kshara sutra treatment, Nagarjuna edition, Varanasi, 1965; p 361- 367.